

Complex auditory musical hallucinations with ambivalent feelings

Hugo Canas-Simião ¹, Sandra Teles Nascimento,² João Reis,² Carina Freitas³

¹Department of Psychiatry, Centro Hospitalar de Lisboa Ocidental EPE, Lisbon, Portugal
²Centro Hospitalar Psiquiátrico de Lisboa, Lisboa, Portugal
³SESARAM, Funchal, Portugal

Correspondence to

Dr Hugo Canas-Simião; hugo.simiao@gmail.com

Accepted 15 October 2021

SUMMARY

A 78-year-old woman with hypertension, diabetes mellitus type 2 and bilateral sensorineural hearing loss was referenced to geriatric psychiatry consultation. She presented cognitive dysfunction, erotomanic delusion and complex musical hallucinations (MH), described as hearing her neighbour singing a familiar church song along with bells in the background, making comments and talking to her. A computed tomography (CT) of the brain detected small right nucleocapsular and bilateral external capsules hypodensities of presumed vascular aetiology during hospitalisation. MH are a rare phenomenon with heterogeneous aetiology. Most frequently, the cause is hearing impairment; other causes include social isolation, cognitive dysfunction, vascular risk factors and medication. Studies suggest that some brain areas related to musical memory circuitry might be related and not fully mapped. Auditory verbal hallucinations with a voice that either comments, talks or sings to the patient have never been described in the literature, making this clinical case attractive.

BACKGROUND

A hallucination is a perception of a sensory stimulus where none exist. Auditory hallucinations are traditionally associated with schizophrenia but can also arise from injury to any portion of the peripheral and central auditory pathways, described in patients with Alzheimer's disease and patients with epilepsy and healthy individuals.^{1 2} They can be simple (static, beeping and humming) or complex (voices and music).

Musical hallucinations (MH) are complex auditory hallucinations that comprise tunes, songs, harmonics, timbres, melodies and rhythms, which are perceived without musical stimuli³ and were first described in 1846 by Jules Baillarger (1806–1891).⁴ They can be repetitive and stereotyped—stable MH—or convoluted and susceptible to remodelling—complex MH.^{3 4} Sacks and Blom described different variants. The prevalence of MH was described as 0.16% of general psychiatric admissions⁵ and as high as 2.5% in older patients with hearing impairment,⁶ but it is overall considered a rare phenomenon and the exact prevalence is not known. The mean age of onset of MH is described to be 56 years, with the majority of patients being female.⁷

Occasionally, they are associated with secondary delusions and accusing others of being responsible for the music, which can severely disable and lead to impaired quality of life and significant distress.⁸ However, according to Berrios, MH is perceived

as a pleasant experience by most patients.⁹ This distinctive significance and pleasant nature of the hallucinations may be related to their heterogeneous aetiologies. Since most patients with MH experience music familiar to them, one can assume that the underlying processes represent abnormal activation of a musical memory circuitry.¹⁰ Recent functional imaging studies unveiled some brain areas that may explain MH.^{11 12} However, the neural circuitry behind MH is yet to be fully mapped.

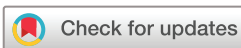The evidence on the treatment of MH is also scarce. Auditory Charles Bonnet syndrome is known to remit following the improvement of hearing.¹³ Case studies report successful treatment of MH with antipsychotics, antidepressants and cognitive enhancers depending on the aetiology.¹⁴ According to a review of MH treatment effects by Coebergh *et al*, 'treatments for musical hallucinations tend to yield favourable results when they target the main etiological factor of these phenomena'. However, according to the previous authors, 'there is a need to establish the natural course of musical hallucinations, their response to non-pharmacological treatments, and their effects on the patient's quality of life'. Aetiological factors may be, however, multiple, entangling the understanding of the natural history of the symptom, the symptom itself and the respective treatment.

Therefore, we describe a rare case of a patient with ambivalent feelings regarding complex MH and discuss their aetiology and treatment.

CASE PRESENTATION

A 78-year-old caucasian woman, illiterate, widow for 15 years, retired for 25 years (had previously worked as a housewife), living with her nephew and one of her three daughters, with a personal medical background of hypertension and diabetes mellitus type 2 was diagnosed with a bilateral hearing loss; she had no relevant familiar psychiatric or medical history. Figures 1–3 show the patient's tympanogram, reflexes and audiogram, respectively. Pure-tone audiogram showed a bilateral and symmetric moderate to severe sensorineural hearing loss. The tympanogram was type As and stapedial reflexes were present bilaterally.

A year after the diagnosis of hearing impairment, she was referenced to geriatric psychiatry for changes in her behaviour and cognitive dysfunction within 2 years of evolution. Besides cognitive dysfunction, she presented erotomanic delusion regarding her neighbour and complex MH. She described it as hearing her neighbour singing a familiar church song along with bells in



© BMJ Publishing Group Limited 2021. No commercial re-use. See rights and permissions. Published by BMJ.

To cite: Canas-Simião H, Nascimento ST, Reis J, *et al*. *BMJ Case Rep* 2021;**14**:e245397. doi:10.1136/bcr-2021-245397

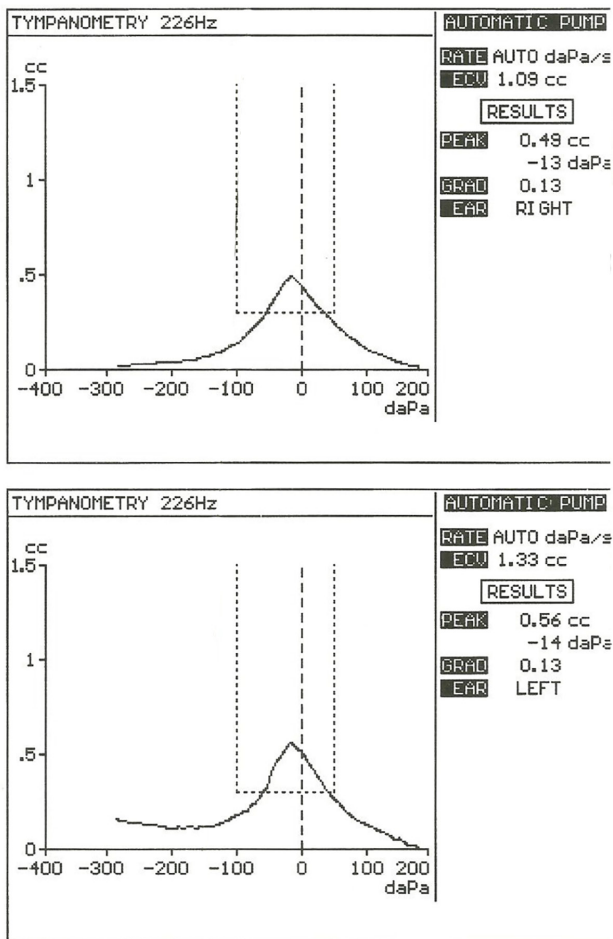


Figure 1 Normal right and left tympanogram.

the background, progressively louder during the day. Sometimes, the song was interrupted with auditory verbal hallucinations of her neighbour's voice making sexual and provoking comments (in the second person) and her neighbour talking to her daughter and spouse, making comments about her (in the third person). Although she was catholic, she did not go to the church for many years, and she never enjoyed music overall.

Moreover, these symptoms were associated with marked distress, especially at night. Interestingly, she felt ambivalent toward her neighbour's voice: sometimes 'his voice' was felt as pleasant, other times distressing and disturbing to her. Listening to music allowed the patient to slightly decrease these phenomena, as she could not identify other alleviators that could change the intensity or the frequency of these auditory hallucinations.

She was then admitted to a psychiatric inpatient unit, where she underwent a complete diagnostic investigation.

INVESTIGATIONS

By the time of admission, a Mini-Mental State Examination (MMSE) was performed, for which she obtained 23/30 (orientation 8/10; registration 3/3; attention and calculation 4/5; recall 2/3; language 6/8 and copying 0/1). Besides cognitive impairment, the patient did not present other significant remarks on the neurologic (including tremor, motricity and sensitivity) and mental state examination. During hospitalisation, the patient completed a blood workup without any findings and underwent

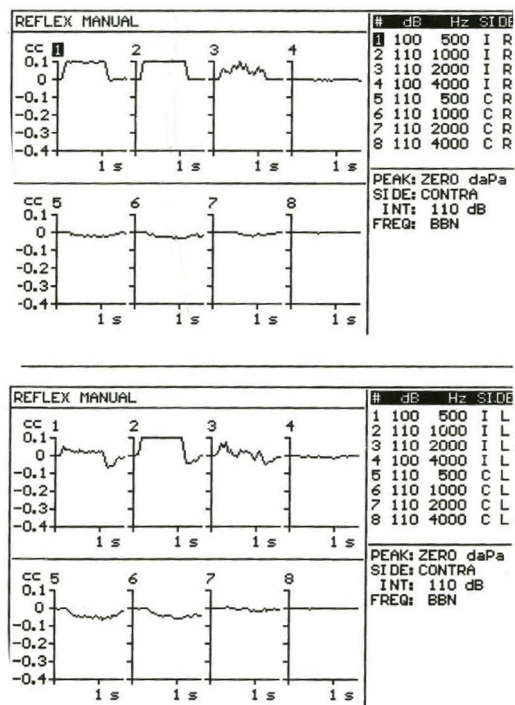


Figure 2 The presence of acoustic reflexes.

a computed tomography (CT) of the brain (figure 4) that detected small right nucleocapsular and bilateral external capsules hypodensities. These are of presumed vascular aetiology, which are associated with diffuse accentuation of the relative hypodensity of the periventricular white substance, which translates to a

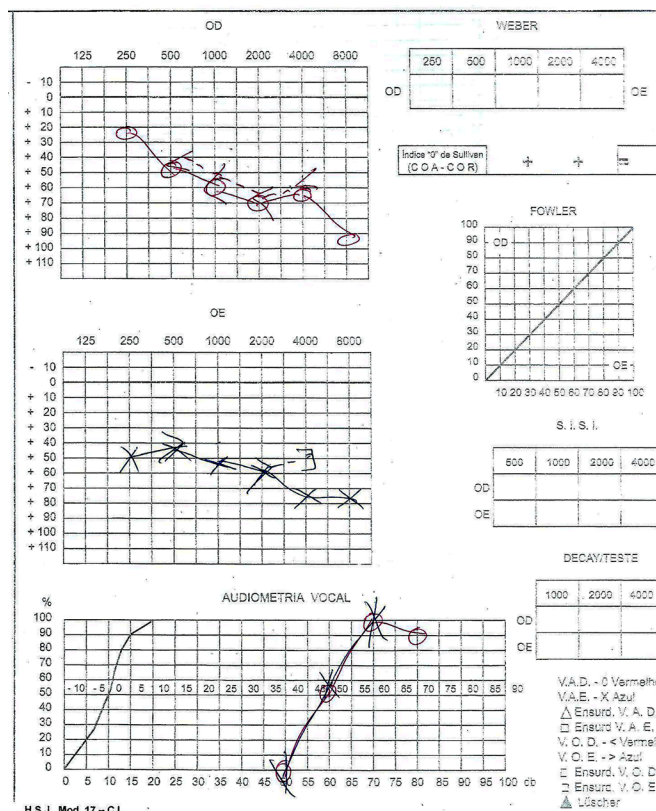


Figure 3 Audiogram showing a bilateral sensorineural hearing loss.

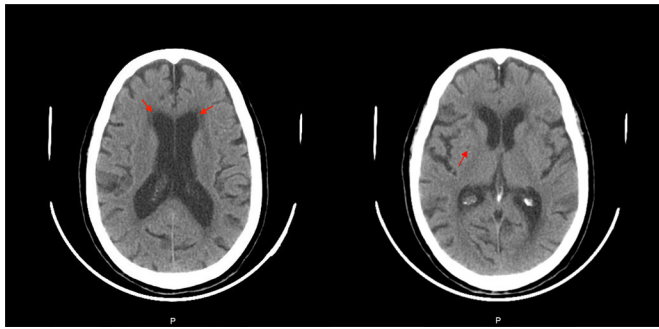


Figure 4 Axial views of cranial CT showing global cortical atrophy. On the left, the red-coloured arrows point to small left and right periventricular hypodensities. On the right, the red-coloured arrow points to right nucleocapsular hypodensities in the right external capsule.

probable pattern of chronic microangiopathic leucoencephalopathy. The electroencephalogram excluded epileptiform activity. The clinical team did not perform a neuropsychological evaluation or MRI of the brain. By the time of discharge, the patient obtained the same MMSE results as at the admission.

DIFFERENTIAL DIAGNOSIS

Overall causes for MH include psychiatric disorders (mainly depression), neurodegenerative disorders, hearing impairment, epilepsy (mainly ictal phenomena; auras with musical features are rare),¹⁵ brain tumours, head injury, encephalitis, multiple sclerosis, substance intoxication,^{7 16} thalamic infarcts, subarachnoid haemorrhage, abnormalities of the auditory cortex,^{17 18} post-concussive syndrome, amyloid beta angiitis, migraine, posterior reversible encephalopathy syndrome and multiple system atrophy.⁷

Although MH usually occur in advanced age and hearing impairment is the most commonly identified predisposing condition, only a minority of these patients develops MH. In this patient, social isolation, cognitive dysfunction, vascular risk factors and multiple medications might be additional contributing factors. We believe all of these factors are contributing to the psychopathology of this patient. In addition, the characteristics of these complex hallucinations might reflect the heterogeneous aetiology: church choral music are typical of neurodegenerative disorders and auditory Charles Bonnet syndrome^{19 20}; auditory verbal hallucinations in the second and third person and erotomanic delusion are typical of schizophrenia and other psychotic spectrum disorders. However, since the latter hypothesis is an exclusion diagnosis according to the main classification systems,^{21 22} the most probable diagnosis is dementia (or major cognitive disorder), vascular or mixed aetiology and psychotic symptoms.

TREATMENT

MH occurring as part of a psychiatric disorder or epilepsy tend to respond well to psychopharmacological treatments targeting the underlying disorder.²³ The multidisciplinary team, including psychiatrists, a neurologist and an internist, discussed the treatment. Despite unsuccessful treatment with olanzapine, risperidone and haloperidol, she obtained a gradual reduction of dynamism of the erotomanic delusion and the auditory hallucinations, with the following medication, for which she was discharged: clozapine 100 mg, zonisamide 100 mg, donepezil 5 mg and memantine 20 mg. The patient did not tolerate

oxcarbazepine due to unbalance and risk of fall. Our patient obtained only a reduction of dynamism of symptoms with an antipsychotic, an anticonvulsant and two antidementials, supporting our hypothesis of an underlying neural circuitry behind MH that is yet to be unveiled.

OUTCOME AND FOLLOW-UP

At discharge, she was in remission of the psychotic symptoms and kept an ambulatory follow-up. The clinical team carried out psychoeducation on the patient and her nephew. During the first follow-up visit after hospitalisation, the patient kept the erotomanic delusion and the complex auditory hallucinations (including music) directed at her neighbour, although with less dynamism and without behavioural impact, with partial insight. Several appointments after, the patient died; the cause of death is not known.

DISCUSSION

Despite being a female and having both a neurodegenerative disorder and a sensorineural hearing loss, both diagnoses are expected in patients with MH described in the literature.^{19 20} However, the most commonly associated dementia is Lewy body dementia, which is not the expected diagnosis in our patient (the absence of visual hallucinations, Parkinsonian signs, autonomic dysfunction, depression or fluctuations of attention). Likewise, auditory hallucinations, especially in the third person, are classically described as Schneider first line of symptoms for schizophrenia, which is an unlikely diagnosis for our patient. Also, although a familiar singing voice is described in the literature,^{24 25} a voice that (besides singing) also comments and talks to the patient is not typical of any specific disorder and is not described in the literature by this paper's submission.

Unlike auditory verbal hallucinations, MH are usually associated with otologic, neurologic or psychiatric disorders, depression being the most common psychiatric aetiology. Therefore, our patient's clinical presentation may result from different affected brain structures that, alongside other case reports, could help in mapping such psychopathology.

Otologic factors

Auditory inputs and auditory hallucinations are considered the result of gamma-band oscillations (approximately 40 Hz) that resonate in the thalamocortical matrix that differ according to functional brain states dependent on the self-restraint from the inner ear.³ Hypoacusis, either age related or due to auditory circuit lesions, may result in loss of inhibitory feedback from peripheral auditory structures and sensory deprivation to the auditory cortices, leading to increased sensitivity and activity of the auditory cortices—a similar phenomenon observed in Charles Bonnet syndrome.²⁶ In a case report of a patient with MH and hypoacusis, hearing aids improved MH; when the patient lost her hearing aids, the MH got worse.²⁴

Neurologic factors

Multiple studies regarding MH seem to converge on the implication of the superior temporal sulcus as the most common underlying activation mechanism.²⁷ Melody selectively activates this auditory association area; activation of the orbitofrontal cortex might be related to some of the emotional characteristics associated with MHs.²⁸ Studies also suggest the orbitofrontal cortex activates in reply to disagreeable music and has a role in the attribution of emotional significance to stimuli¹¹; the same authors hypothesises a brain basis for MH. PET imaging studies

Case report

during active MH also showed that the posterior aspect of the temporal lobes, right basal ganglia, inferior frontal cortices, thalamus, brainstem, pons, cerebellum and auditory radiations were active while the primary auditory cortex was not.^{12 26} The frontal speech areas,²⁸ anterior cingulate²⁹ left anterior superior temporal gyrus, the motor cortex and posteromedial cortex also might have a role in the generation of MH.^{2 11 27 30}

Vascular brain lesions can have heterogeneous clinical presentations. Since our patient's CT shows right nucleocapsular and bilateral external capsules lesions, we believe these areas may also be related to MH, particularly with ambivalent feelings, as exemplified by our patient's clinical presentation. Furthermore, our findings are consistent with previous studies that show that MHs are associated with primarily bilateral functional changes, with a minor leaning to the right.^{27 31}

Psychiatric disorders and neurotransmitters

MH are different from auditory verbal hallucinations seen in primary affective and psychotic disorders. Patients generally have insight into their MH and usually do not demonstrate other symptoms consistent with psychotic disorders.²⁶ Depressive disorders were reported in one-third of senior patients with MH, and, in all cases, treatment of depression improved MH.²⁶ Despite evidence of serotonin involvement in MH and auditory processing,^{32 33} our patient did not show symptoms compatible with a depressive illness; a trial with an antidepressant could be, however, beneficial. Citalopram showed benefit along with cognitive behavioral therapy (CBT).³⁴ Three per cent to 15% of patients with MH have schizophrenia, yet studies with both entities are scarce.²⁶ Our patient, however, presents auditory verbal hallucinations in the second and third person and erotomanic delusion, which are typical of schizophrenia and other psychotic spectrum disorders. Psychotic symptoms are classically associated with an impairment in dopaminergic pathways, mainly within the dorsal rather than the limbic striatum.³⁵ More so, dopaminergic neurotransmission is involved in musical anticipation and pleasure while listening to music and has a role in music and auditory processing through primary temporal, prefrontal and temporoparietal associative areas and the limbic system.^{36 37} Two successful cases treated with quetiapine³⁸; limited advantages were observed with other antipsychotics.²⁶

Non-pathological phenomena

It is worth noting that voluntary (creative thought) and involuntary ('earworms') musical imagery are internal phenomena ('inner music'),³⁹ while MH are, by definition, external. MH are also less frequent, less controllable and usually less familiar³⁹ than the former.

MH can remit without intervention and, when they do not, since some are bearable/enjoyable, intervention is not needed.²³ However, in some patients, MH are so disturbing that treatment is indicated. The response to treatment seems to depend on aetiology.²³ In cases of auditory Charles Bonnet syndrome, treating the hearing impairment (hearing aids) and coping strategies (eg, more acoustic stimulation) can improve the symptom; cholinergic enhancers like donepezil can also be helpful.^{26 40} In fact, a cholinergic deficit is described as being associated with MH.³⁷ Acetylcholine mediates inner hair cells depolarisation, and hyperpolarisation seems to have a role in recognising signals in a noisy environment, involving pathways to the cochlear nucleus.³⁷

Learning points

- ▶ Musical hallucinations (MH) can be present with a heterogeneous aetiology, like our patient.
- ▶ Since patients with MH experience music familiar to them, underlying processes may represent abnormal activation of a musical memory circuitry (in which the posterior temporal lobes, right basal ganglia, inferior frontal cortices and frontal speech areas seem to be involved but are yet to be fully mapped).
- ▶ Despite typical descriptions of MH, a familiar specific singing voice that also comments and talks to the patient is not typical of a specific disorder and has never been described in the literature until this date.
- ▶ Our patient's CT of the brain revealed small right nucleocapsular hypodensities and bilateral external capsules of presumed vascular aetiology.
- ▶ We believe the publishing of case reports where CT of specific brain lesions are presented may help build a map of this circuitry and explain the fascinating phenomena of MH.

Acknowledgements We thank Sara Fernandes Custódio, Ana Velosa and Bruno Silva for helping with the interpretation of the complementary diagnostic exams.

Contributors HC-S monitored data collection, analysed the data and drafted and revised the paper. STN analysed the data and revised the paper. JR provided data collection and revised the paper. CF initiated the project, designed and monitored data collection, analysed the data and validated and revised the paper.

Funding The authors have not declared a specific grant for this research from any funding agency in the public, commercial or not-for-profit sectors.

Competing interests None declared.

Patient consent for publication Consent obtained from parent(s)/guardian(s).

Provenance and peer review Not commissioned; externally peer reviewed.

ORCID iD

Hugo Canas-Simião <http://orcid.org/0000-0001-8100-8589>

REFERENCES

- 1 Korsnes MS, Hugdahl K, Nygård M, *et al*. An fMRI study of auditory hallucinations in patients with epilepsy. *Epilepsia* 2010;51:610–7.
- 2 Krabbendam L, van Os J. Schizophrenia and urbanicity: a major environmental influence-conditional on genetic risk. *Schizophr Bull* 2005;31:795–9.
- 3 Blom JD. *Auditory hallucinations*. 1st edn. Elsevier BV, 2015.
- 4 Sacks OW, Blom JD. Musical hallucinations. In: Blom JD, Sommer IEC, eds. *Hallucinations: research and practice*. New York, NY: Springer, 2012: 133–42.
- 5 Alvarez Perez P, Garcia-Antelo MJ, Rubio-Nazabal E. "Doctor, I Hear Music": A Brief Review About Musical Hallucinations. *Open Neurol J* 2017;11:11–14.
- 6 Cole MG, Dowson L, Dendukuri N, *et al*. The prevalence and phenomenology of auditory hallucinations among elderly subjects attending an audiology clinic. *Int J Geriatr Psychiatry* 2002;17:444–52.
- 7 Golden EC, Josephs KA. Minds on replay: musical hallucinations and their relationship to neurological disease. *Brain* 2015;138:3793–802.
- 8 Coebergh JAF, Lauw RF, Bots R, *et al*. Musical hallucinations: review of treatment effects. *Front Psychol* 2015;6:814.
- 9 Berrios GE. Musical hallucinations. A historical and clinical study. *Br J Psychiatry* 1990;156:188–94.
- 10 Vitorovic D, Biller J. Musical hallucinations and forgotten tunes – case report and brief literature review. *Front Neurol* 2013;4:2013–5.
- 11 Kumar S, Sedley W, Barnes GR, *et al*. A brain basis for musical hallucinations. *Cortex* 2014;52:86–97.
- 12 Griffiths TD. Musical hallucinosis in acquired deafness: phenomenology and brain substrate. *Brain* 2000;123:2065–76.
- 13 Patel HC, Keshavan MS, Martin S. A case of Charles Bonnet syndrome with musical hallucinations. *Can J Psychiatry* 1987;32:303–4.
- 14 Strauss M, Gertz H-J. Treatment of musical hallucinosis with acetylcholinesterase inhibitors. *J Neurol Neurosurg Psychiatry* 2009;80:1298–9.
- 15 Coebergh JAF, Lauw RF, Sommer IEC, *et al*. Musical hallucinations and their relation with epilepsy. *J Neurol* 2019;266:1501–15.

- 16 Doluweera Y, Suraweera C. Those who hear music: three cases on musical hallucinations. *Case Rep Psychiatry* 2018;2018:9361382.
- 17 Hermesh H, Konas S, Shiloh R, *et al*. Musical hallucinations: prevalence in psychotic and nonpsychotic outpatients. *J Clin Psychiatry* 2004;65:191–7.
- 18 Schakenraad SMM, Teunisse RJ, Olde Rikkert MGM. Musical hallucinations in psychiatric patients. *Int J Geriatr Psychiatry* 2006;21:394–7.
- 19 Kukstas C. Auditory Charles Bonnet syndrome: case report. *Br J Gen Pract* 2019;69:362–3.
- 20 Golden EC, Josephs KA. Minds on replay: Musical hallucinations and their relationship to neurological disease. *Brain* 2015;138:3793–802.
- 21 Americans N, Article S, Haghiri H. The ICD-10 classification of mental and behavioural disorders. In: *IACAPAP e-Textbook of child and adolescent mental health*. , 2013: 55, 135–9.
- 22 Hidalgo Vicario MH, Rodríguez Hernández PR. DSM-5. manual diagnóstico y estadístico de los trastornos mentales. últimas novedades 2013.
- 23 Coebergh JAF, Lauw RF, Bots R, *et al*. Musical hallucinations: review of treatment effects. *Front Psychol* 2015;6:1–11.
- 24 Kinson RM, Lim WP, Rahman H. Alive with the sound of music: a case series on patients presenting with musical hallucinations in a general Hospital. *J Neuropsychiatry Clin Neurosci* 2015;27:e51–3.
- 25 Hammeke TA, McQuillen MP, Cohen BA. Musical hallucinations associated with acquired deafness. *J Neurol Neurosurg Psychiatry* 1983;46:570–2.
- 26 Zein M, Sher Y. Musical Memories—Musical hallucinations in a lung transplant recipient: case report and literature review. *Psychosomatics* 2020.
- 27 Bernardini F, Attademo L, Blackmon K, *et al*. Musical hallucinations: a brief review of functional neuroimaging findings. *CNS Spectr* 2017;22:397–403.
- 28 Luterveld Rvan, Sommer IEC, Ford JM. The neurophysiology of auditory hallucinations – a historical and contemporary review. *Front Psychiatry* 2011;2:28.
- 29 Schmitgen A, Saal J, Sankaran N, *et al*. Musical hallucinations in chronic pain: the anterior cingulate cortex regulates internally generated percepts. *Front Neurol* 2021;12:669172.
- 30 Freitas C, Manzano E, Burini A, *et al*. Neural correlates of Familiarity in music listening: a systematic review and a neuroimaging meta-analysis. *Front Neurosci* 2018;12:686.
- 31 Buchwald N, Kelly A, Heilman KM, *et al*. Musical hallucinations with a right frontotemporal stroke. *Neurocase* 2020;26:313–6.
- 32 Fornaro M, Martino M. Tinnitus psychopharmacology: a comprehensive review of its pathomechanisms and management. *Neuropsychiatr Dis Treat* 2010;6:209–18.
- 33 Hurley LM, Hall IC. Context-Dependent modulation of auditory processing by serotonin. *Hear Res* 2011;279:74–84.
- 34 van Veen SMP, Scheurleer WFJ, Ruijsch ML, *et al*. Last-minute recovery of a psychiatric patient requesting physician-assisted death. *Psychiatric Services* 2020;71:621–3.
- 35 McCutcheon RA, Abi-Dargham A, Howes OD. Schizophrenia, dopamine and the striatum: from biology to symptoms. *Trends Neurosci* 2019;42:205–20.
- 36 Zatorre RJ, Salimpoor VN. From perception to Pleasure: music and its neural substrates. *Proc Natl Acad Sci U S A* 2013;110:10430–7.
- 37 Appler JM, Goodrich LV. Connecting the ear to the brain: molecular mechanisms of auditory circuit assembly. *Prog Neurobiol* 2011;93:488–508.
- 38 Kitamura H, Saito M, Someya T. Two cases of musical hallucination successfully treated with quetiapine. *Psychiatry Clin Neurosci* 2017;71:789.
- 39 Moseley P, Alderson-Day B, Kumar S, *et al*. Musical hallucinations, musical imagery, and earworms: a new phenomenological survey. *Conscious Cogn* 2018;65:83–94.
- 40 Singh A, Karasin J, Madhusoodanan S. The sound of music: a rare case of auditory Charles Bonnet syndrome in an elderly male. *Ann Clin Psychiatry* 2019;31:107–10.

Copyright 2021 BMJ Publishing Group. All rights reserved. For permission to reuse any of this content visit <https://www.bmj.com/company/products-services/rights-and-licensing/permissions/>
BMJ Case Report Fellows may re-use this article for personal use and teaching without any further permission.

Become a Fellow of BMJ Case Reports today and you can:

- ▶ Submit as many cases as you like
- ▶ Enjoy fast sympathetic peer review and rapid publication of accepted articles
- ▶ Access all the published articles
- ▶ Re-use any of the published material for personal use and teaching without further permission

Customer Service

If you have any further queries about your subscription, please contact our customer services team on +44 (0) 207111 1105 or via email at support@bmj.com.

Visit casereports.bmj.com for more articles like this and to become a Fellow